

## Tokyo Guidelines 2018: initial management of acute biliary infection and flowchart for acute cholangitis

Fumihiko Miura · Kohji Okamoto · Tadahiro Takada · Steven M. Strasberg · Horacio J. Asbun · Henry A. Pitt · Harumi Gomi · Joseph S. Solomkin · David Schlossberg · Ho-Seong Han · Myung-Hwan Kim · Tsann-Long Hwang · Miin-Fu Chen · Wayne Shih-Wei Huang · Seiki Kiriya · Takao Itoi · O. James Garden · Kui-Hin Liao · Akihiko Horiguchi · Keng-Hao Liu · Cheng-Hsi Su · Dirk J. Gouma · Giulio Belli · Christos Dervenis · Palepu Jagannath · Angus C. W. Chan · Wan Yee Lau · Itaru Endo · Kenji Suzuki · Yoo-Seok Yoon · Eduardo de Santibañes · Mariano Eduardo Giménez · Eduard Jonas · Harjit Singh · Goro Honda · Koji Asai · Yasuhisa Mori · Keita Wada · Ryota Higuchi · Manabu Watanabe · Toshiki Rikiyama · Naohiro Sata · Nobuyasu Kano · Akiko Umezawa · Shuntaro Mukai · Hiromi Tokumura · Jiro Hata · Kazuto Kozaka · Yukio Iwashita · Taizo Hibi · Masamichi Yokoe · Taizo Kimura · Seigo Kitano · Masafumi Inomata · Koichi Hirata · Yoshinobu Sumiyama · Kazuo Inui · Masakazu Yamamoto

Published online: 8 January 2018

© 2018 Japanese Society of Hepato-Biliary-Pancreatic Surgery

The author's affiliations are listed in the Appendix.

Correspondence to: Tadahiro Takada, Department of Surgery, Teikyo University School of Medicine, 2-11-1 Kaga, Itabashi-ku, Tokyo 173-8605, Japan  
e-mail: t-takada@jshbps.jp

DOI: 10.1002/jhbp.509

**Abstract** The initial management of patients with suspected acute biliary infection starts with the measurement of vital signs to assess whether or not the situation is urgent. If the case is judged to be urgent, initial medical treatment should be started immediately including respiratory/circulatory management if required, without waiting for a definitive diagnosis. The patient's medical history is then taken; an abdominal examination is performed; blood tests, urinalysis, and diagnostic imaging are carried out; and a diagnosis is made using the diagnostic criteria for cholangitis/cholecystitis. Once the diagnosis has been confirmed, initial medical treatment should be started immediately, severity should be assessed according to the severity grading criteria for acute cholangitis/cholecystitis, and the patient's general status should be evaluated. For mild acute cholangitis, in most cases initial treatment including antibiotics is sufficient, and most patients do not require biliary drainage. However, biliary drainage should be considered if a patient does not respond to initial treatment. For moderate acute cholangitis, early endoscopic or percutaneous transhepatic biliary drainage is indicated. If the underlying etiology requires treatment, this should be provided after the patient's general condition has improved; endoscopic sphincterotomy and subsequent choledocholithotomy may be performed together with biliary drainage. For severe acute cholangitis, appropriate respiratory/circulatory management is required. Biliary drainage should be performed as soon as possible after the patient's general condition has been improved by initial treatment and respiratory/circulatory management. Free full articles and mobile app of TG18 are available at: [http://www.jshbps.jp/modules/en/index.php?content\\_id=47](http://www.jshbps.jp/modules/en/index.php?content_id=47). Related clinical questions and references are also included.

**Keywords** Acute cholangitis · Acute cholecystitis · Biliary drainage · Guidelines · Initial treatment

## Introduction

Acute biliary infection, particularly acute cholangitis, may cause a rapid deterioration in condition due to sepsis, and prompt and appropriate treatment is therefore required. There were no clear management guidelines available until 2007, when we first proposed a flowchart illustrating guidelines for the management of acute cholangitis and acute cholecystitis according to the severity grades in the Tokyo Guidelines 2007 (TG07) [1]. The TG07 flowchart was established on the basis of the consensus reached in the International Consensus Meeting held in Tokyo in April 2006. The TG07 flowchart has been cited in numerous publications and has had a major impact on everyday clinical practice and clinical research [2]. The Tokyo Guidelines were revised in 2013 as the Tokyo Guidelines 2013 (TG13) [2], and the Tokyo Guidelines 2018 (TG18) is the third revised version.

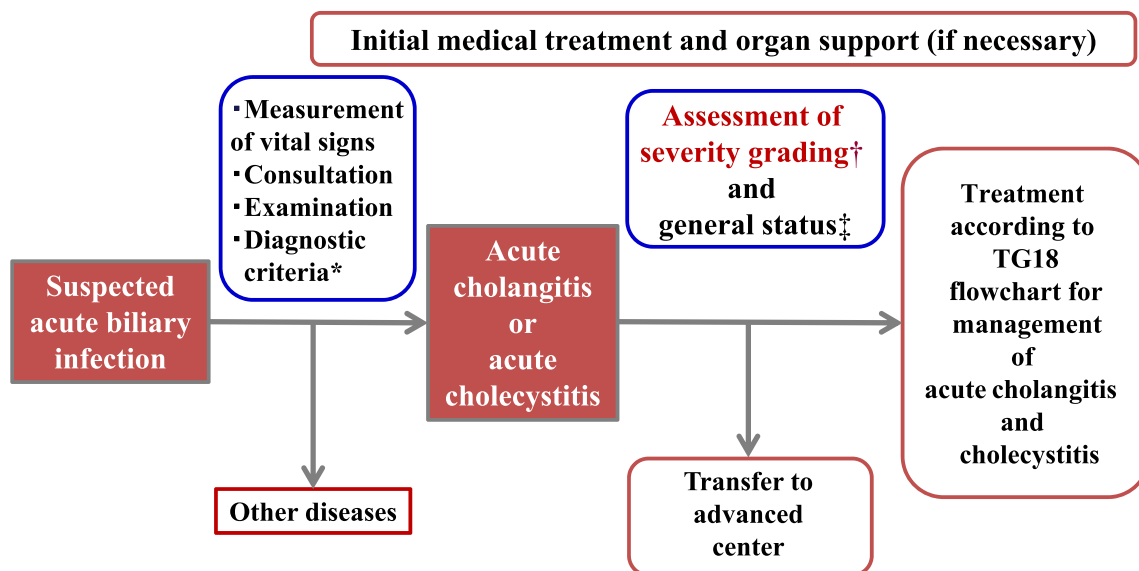
In TG18, part of the flowchart for the management of moderate acute cholangitis has been somewhat revised from TG13. The flowchart for the management of acute cholecystitis, however, has undergone major revisions compared with TG13. In TG07 and TG13, the flowcharts for the management of acute cholangitis and acute cholecystitis were published together in a single paper, but for the TG18 the initial response to acute biliary infection and the flowchart for management of acute cholangitis are dealt with in this paper, while the flowchart for the management of acute cholecystitis is reported in a separate publication [3].

## Flowchart for the initial response to acute biliary infection

The initial management (Fig. 1) of patients with suspected acute biliary infection starts with the measurement of vital signs to assess whether or not the situation is urgent. If the case is judged to be urgent, initial medical treatment should be started immediately including respiratory/circulatory management if required, without waiting for the definitive diagnosis.

A detailed examination (consultation and physical examination) is then performed, after which blood tests and diagnostic imaging are performed; on the basis of the results, a definitive diagnosis is made following the diagnostic criteria for acute cholangitis and cholecystitis (clinical practice guidelines, CPG) [4–9].

Once the diagnosis has been confirmed, initial medical treatment should be started immediately, the severity should be assessed according to the severity grading criteria for acute cholangitis/cholecystitis, and the patient's general status should be evaluated. The Charlson comorbidity index (CCI) (case series, CS) [10] and the American Society of Anesthesiologists (ASA) Physical Status (PS) classification [11] are useful for the evaluation of general status. After the severity assessment, a treatment strategy should be decided on the basis of the flowchart for the management of acute cholangitis or acute cholecystitis, and treatment should immediately be provided.



**Fig. 1** TG18 flowchart for the initial response to acute biliary infection. \*TG18/TG13 diagnostic criteria for acute cholangitis [4] and cholecystitis [7] should be used. †TG18/TG13 severity assessment criteria for acute cholangitis [4] and cholecystitis [7] should be used. ‡Charlson comorbidity index (CCI) [10] and the American Society of Anesthesiologists (ASA) Physical Status (PS) classification [11] should be referred to

General status and signs when acute biliary infection is suspected

Symptoms indicative of suspected acute biliary infection are fever, chills, abdominal pain, jaundice, nausea, vomiting, and disturbance of consciousness. If even one of these symptoms is present, acute biliary infection is suspected and it is necessary to proceed to diagnosis (CPG) [12].

Management of patients with suspected acute biliary infection

Vital signs include blood pressure, heart rate, respiration rate, temperature, urine volume, oxygen saturation (SpO<sub>2</sub>), and consciousness level. The consultation should include a detailed medical history of the timing of the appearance of symptoms and their nature. Patients should be asked about their previous medical history and regular medications. In the physical examination, the evaluation and measurement of the patient's state of consciousness goes without saying, and the presence or absence of yellowing of the palpebral conjunctiva, the location and severity of tenderness, and whether or not there are any symptoms of peritoneal irritation must always be confirmed. The presence or absence of Murphy's sign (compression of the right upper quadrant causes the patient to catch their breath due to pain when taking a deep breath), which is specific to acute cholecystitis, must always be confirmed.

Tests required for the diagnosis of acute biliary infection

Blood tests including white blood cell count, platelet count, C-reactive protein (CRP), albumin, alkaline phosphatase (ALP), gamma-glutamyl transferase (GGT), aspartate aminotransferase (AST), alanine aminotransferase (ALT), bilirubin, blood urea nitrogen (BUN), creatinine, prothrombin time (PT), and PT-international normalized ratio (INR) are carried out for the purpose of diagnosis and severity grading, and blood gas analysis should also be performed (CPG) [12]. If a high fever is present, blood culture should preferably be performed at this point.

In terms of diagnostic imaging, abdominal ultrasound and computed tomography (CT) are useful for the diagnosis of acute biliary infection, and at least one of these should be performed. Abdominal ultrasound in particular is minimally invasive, widely used, simple, and cheap, and should therefore be performed first in patients with suspected biliary infection, despite disadvantages including the fact that the results are easily affected by the operator's skill and the patient's condition (CPG) [6].

Inflammation in acute cholangitis is difficult to assess on diagnostic imaging, but it is possible to evaluate dilatation of the bile duct, or bile congestion due to occlusion/stenosis of the bile duct or biliary calculus and its cause (CPG) [12].

The distinctive signs of acute cholecystitis on diagnostic imaging include enlargement of the gallbladder, gallbladder wall thickening, gallbladder calculi, fluid retention around the gallbladder, abscess around the gallbladder, and sludge debris in the gallbladder and the sonographic Murphy's sign (pain when the probe presses on the gallbladder) on abdominal ultrasound (CPG) [12].

Diagnostic criteria for acute biliary infection

Diagnosis is made in light of the findings required for diagnosis, as described above, using the TG13/18 diagnostic criteria for acute cholangitis (Table 1) (CPG) [4–6] and the TG13/18 diagnostic criteria for acute cholecystitis (Table 2) (CPG) [8, 9].

Initial treatment

Once a definitive diagnosis of acute cholangitis or acute cholecystitis has been reached, initial treatment including the infusion of sufficient fluids and antibiotic and analgesic administration is started, with careful monitoring of blood pressure, heart rate, and urine volume. It goes without saying that if the patient is in a state of shock, initial treatment should be started without waiting for a definitive diagnosis. Although there is no high-quality evidence for the merits and demerits of fasting in acute cholangitis/cholecystitis, in principle patients should be fasted to enable immediate emergency drainage (CPG) [12]. Despite the concern that analgesic administration may mask physical signs and cause a mistaken diagnosis, a randomized controlled trial (RCT) comparing intravenous morphine hydrochloride and an intravenous placebo for patients examined in the emergency room complaining of abdominal pain found no difference between them in the rate of diagnosis [13, 14], and analgesics should therefore be administered proactively at an early stage. Opioid analgesics such as morphine hydrochloride and other similar types of drug (such as non-opioid analgesics and pentazocine) cause the sphincter of Oddi to contract, which may elevate biliary pressure, and must therefore be administered with caution.

In the case of serious deterioration, such as the appearance of shock (hypotension), disturbance of consciousness, acute dyspnea, acute renal dysfunction, hepatic

**Table 1** TG18/TG13 diagnostic criteria for acute cholangitis

A. Systemic inflammation			
A-1. Fever and/or shaking chills			
A-2. Laboratory data: evidence of inflammatory response			
B. Cholestasis			
B-1. Jaundice			
B-2. Laboratory data: abnormal liver function tests			
C. Imaging			
C-1. Biliary dilatation			
C-2. Evidence of the etiology on imaging (stricture, stone, stent, etc)			
<b>Suspected diagnosis:</b> one item in A + one item in either B or C			
<b>Definite diagnosis:</b> one item in A, one item in B and one item in C			
A-2: Abnormal white blood cell counts, increase of serum C-reactive protein levels, and other changes indicating inflammation			
B-2: Increased serum ALP, r-GTP (GGT), AST, and ALT levels			
Thresholds			
A-1	Fever		BT >38°C
A-2	Evidence of inflammatory response	WBC ( $\times 1,000/\mu\text{l}$ )	<4 or >10
		CRP (mg/dl)	$\geq 1$
B-1	Jaundice		T-Bil $\geq 2$ (mg/dl)
B-2	Abnormal liver function tests	ALP (IU)	$>1.5 \times \text{STD}$
		$\gamma\text{GTP}$ (IU)	$>1.5 \times \text{STD}$
		AST (IU)	$>1.5 \times \text{STD}$
		ALT (IU)	$>1.5 \times \text{STD}$

Cited from Kiriyama et al. [4]

ALP alkaline phosphatase, ALT alanine aminotransferase, AST aspartate aminotransferase, rGTP (GGT) r-glutamyltransferase, STD upper limit of normal value

**Table 2** TG18/TG13 diagnostic criteria for acute cholecystitis

A. Local signs of inflammation etc.	
(1) Murphy's sign, (2) RUQ mass/pain/tenderness	
B. Systemic signs of inflammation etc.	
(1) Fever, (2) elevated CRP, (3) elevated WBC count	
C. Imaging findings	
Imaging findings characteristic of acute cholecystitis	

**Suspected diagnosis:** one item in A + one item in B

**Definite diagnosis:** one item in A + one item in B + C

Cited from Yokoe et al. [7]. Acute hepatitis, other acute abdominal diseases, and chronic cholecystitis should be excluded

CRP C-reactive protein, RUQ right upper abdominal quadrant, WBC white blood cell

dysfunction, or disseminated intravascular coagulation (DIC) (reduced platelet count), emergency biliary drainage should be considered alongside appropriate organ support and respiratory/circulatory management (such as artificial ventilation, tracheal intubation, and the use of hypertensive agents) (CPG) [12].

For guidance on antibiotic administration, see TG18: antimicrobial therapy for acute cholangitis and cholecystitis (CPG) [15].

#### Severity assessment and general status evaluation

Alongside initial treatment, severity assessment should be carried out using the TG13/18 severity assessment criteria for acute cholangitis (Table 3) (CPG) [4–6] or the TG13/18 severity assessment criteria for acute cholecystitis (Table 4) (CPG) [8, 9], and the patient's general status should also be evaluated using the CCI and the ASA-PS classification. The severity should be reassessed frequently in accordance with response to initial treatment.

If the patient cannot be treated appropriately, transfer should be considered to an advanced center capable of procedures including emergency surgery, interventional radiology (IVR), and endoscopy.

#### Q1. How was the TG13 flowchart for acute cholangitis evaluated? [Background question]

**It was shown to require partial revision. (Level D)**

Although no studies have evaluated the flowchart itself, a review was carried out of studies that included partial investigations of the treatment guidelines for acute cholangitis set out in the flowchart. Two observational studies addressed the timing of biliary drainage by severity grade. A multicenter joint study carried out in Japan and Taiwan found that for moderate cholangitis, mortality was significantly lower in 944 patients who underwent drainage within 24 h compared with 1,081 patients who either underwent drainage after longer than 24 h or did not undergo drainage (1.7% vs. 3.4%,  $P = 0.0172$ ), but that there was no significant difference for mild or severe cholangitis [16]. In the other observational study, which compared 130 patients with mild or moderate cholangitis who underwent drainage within 24 h and 82 who underwent drainage after longer than 24 h, although there was no significant difference in mortality which was zero in both groups, the mean duration of hospitalization was significantly shorter for patients who underwent drainage within 24 h (6.8 days vs. 9.2 days,  $P < 0.01$  (CS) [17].

The TG13 flowchart proposed that for patients with moderate cholangitis, treatment for the underlying etiology should be provided electively after early biliary drainage, and that for patients with mild cholangitis due to choledocholithiasis, treatment for the underlying etiology such as endoscopic sphincterotomy (EST) and choledocholithotomy may be performed at the same time as biliary drainage [12]. Three observational studies (one of which did

**Table 3** TG18/TG13 severity assessment criteria for acute cholangitis

## Grade III (severe) acute cholangitis

“Grade III” acute cholangitis is defined as acute cholangitis that is associated with the onset of dysfunction at least in any one of the following organs/systems:

1. Cardiovascular dysfunction: hypotension requiring dopamine  $\geq 5$   $\mu\text{g}/\text{kg}$  per min, or any dose of norepinephrine
2. Neurological dysfunction: disturbance of consciousness
3. Respiratory dysfunction:  $\text{PaO}_2/\text{FiO}_2$  ratio  $< 300$
4. Renal dysfunction: oliguria, serum creatinine  $> 2.0$  mg/dl
5. Hepatic dysfunction: PT-INR  $> 1.5$
6. Hematological dysfunction: platelet count  $< 100,000/\text{mm}^3$

## Grade II (moderate) acute cholangitis

“Grade II” acute cholangitis is associated with any two of the following conditions:

1. Abnormal WBC count ( $> 12,000/\text{mm}^3$ ,  $< 4,000/\text{mm}^3$ )
2. High fever ( $\geq 39^\circ\text{C}$ )
3. Age ( $\geq 75$  years)
4. Hyperbilirubinemia (total bilirubin  $\geq 5$  mg/dl)
5. Hypoalbuminemia ( $< \text{STD} \times 0.7$ )

## Grade I (mild) acute cholangitis

“Grade I” acute cholangitis does not meet the criteria of “Grade III (severe)” or “Grade II (moderate)” acute cholangitis at initial diagnosis

Cited from Kiriyama et al. [4]

STD lower limit of normal value

**Table 4** TG18/TG13 severity grading for acute cholecystitis

## Grade III (severe) acute cholecystitis

Associated with dysfunction of any one of the following organs/systems:

1. Cardiovascular dysfunction: hypotension requiring treatment with dopamine  $\geq 5$   $\mu\text{g}/\text{kg}$  per min, or any dose of norepinephrine
2. Neurological dysfunction: decreased level of consciousness
3. Respiratory dysfunction:  $\text{PaO}_2/\text{FiO}_2$  ratio  $< 300$
4. Renal dysfunction: oliguria, serum creatinine  $> 2.0$  mg/dl
5. Hepatic dysfunction: PT-INR  $> 1.5$
6. Hematological dysfunction: platelet count  $< 100,000/\text{mm}^3$

## Grade II (moderate) acute cholecystitis

Associated with any one of the following conditions:

1. Elevated white blood cell count ( $> 18,000/\text{mm}^3$ )
2. Palpable tender mass in the right upper abdominal quadrant
3. Duration of complaints  $> 72$  h
4. Marked local inflammation (gangrenous cholecystitis, pericholecystic abscess, hepatic abscess, biliary peritonitis, emphysematous cholecystitis)

## Grade I (mild) acute cholecystitis

Does not meet the criteria of “Grade III” or “Grade II” acute cholecystitis. Grade I can also be defined as acute cholecystitis in a healthy patient with no organ dysfunction and mild inflammatory changes in the gallbladder, making cholecystectomy a safe and low risk operative procedure

Cited from Yokoe et al. [7]

not use severity assessment criteria) (CS) [17–19] and one RCT [20] showed that single-stage lithotomy was safe and feasible in cases of mild or moderate acute cholangitis caused by choledocholithiasis. In the RCT, however, the rate of complications after endoscopic retrograde cholangiopancreatography (ERCP) was significantly higher than

that after two-stage lithotomy (6/35 = 17.1% vs. 0/33 = 0%,  $P = 0.025$ ) (RCT) [20]; therefore, caution is required.

Two studies have compared early and elective laparoscopic choledocholithotomy for patients with mild or moderate acute cholangitis associated with choledocholithiasis

(CS) [21, 22]. Early laparoscopic choledocholithotomy was safe and there was no difference in the rate of complications, but both studies were carried out in the same institution, included few subjects [72 (CS) [21] and 73 (CS) [22], respectively] with a large number of exclusions, and did not demonstrate the safety of single-stage laparoscopic choledocholithotomy in patients with moderate acute cholangitis.

At this point, although the value of the TG13 flowchart for acute cholangitis as a whole is unclear, its core structure is based on conservative treatment in mild cases and early biliary drainage in moderate cases, and as the value of these has been shown in large-scale studies to be highly significant, the value of the flowchart has been demonstrated to at least some extent. Although the evidence for single-stage treatment for the underlying etiology in moderate acute cholangitis (EST followed by choledocholithotomy) is still insufficient, the TG18 flowchart for acute cholangitis has been amended to show that this is possible in light of the actual situation in clinical practice.

**Q2. What treatments other than antibiotics and biliary drainage are effective for severe cholangitis? [Future research question]**

**The administration of recombinant human soluble thrombomodulin may be considered for severe cholangitis complicated with disseminated intravascular coagulation. (Level D)**

Severe cholangitis is often complicated by DIC. Septic DIC is treated with anticoagulants such as heparin, antithrombin III, and protease inhibitors. Although these anticoagulants have been well studied, including in RCTs, the numbers of cholangitis patients in these studies are either unknown or very small, and the value of anticoagulants in severe cholangitis is unclear. Two studies have reported the value of recombinant human soluble thrombomodulin (rTM) for DIC in patients with acute cholangitis (CS) [23, 24]. Suetani et al. divided 66 patients diagnosed with acute cholangitis-induced DIC on the basis of the TG13 diagnostic criteria into 33 who were treated with rTM and 36 who were not, and found that the DIC resolution rate was significantly better in patients given rTM (83.3% vs. 52.8%,  $P < 0.01$ ), but that there was no significant difference in mortality (13.3% vs. 27.8%,  $P = 0.26$ ) (CS) [23]. In a study by Nakahara et al. of 13 patients with acute cholangitis-induced DIC, seven patients who were treated with rTM had significantly lower DIC scores compared with six who were only treated with antithrombin III (CS) [24]. Both those studies were case series with insufficient numbers of patients to provide more than a low level

of evidence, but as there were no serious side-effects, the use of rTM in patients with severe cholangitis complicated by DIC may be considered.

**Flowchart for the management of acute cholangitis and cholecystitis**

After severity has been assessed and the patient's general status has been evaluated, a treatment strategy should be decided on the basis of the flowchart for the management of acute cholangitis or acute cholecystitis, and treatment should immediately be provided.

With the exception of part of the management of moderate cholangitis, the TG18 flowchart for the management of acute cholangitis is little changed from TG13 (CPG) [12]. Acute cholangitis should be managed in accordance with its severity. Biliary drainage and antibiotics are the two key pillars of the treatment of acute cholangitis. In some cases of acute cholangitis, acute cholecystitis may also be present; in this event the treatment strategy should be decided in consideration of the severity of both and the patient's general status (CPG) [12]. If blood culture has not been performed as part of the initial response, it should be carried out before antibiotic administration. If biliary drainage is performed, bile samples must always be sent for culture.

For the flowchart for the management of acute cholecystitis, see TG18: flowchart for the management of acute cholecystitis (CPG) [3].

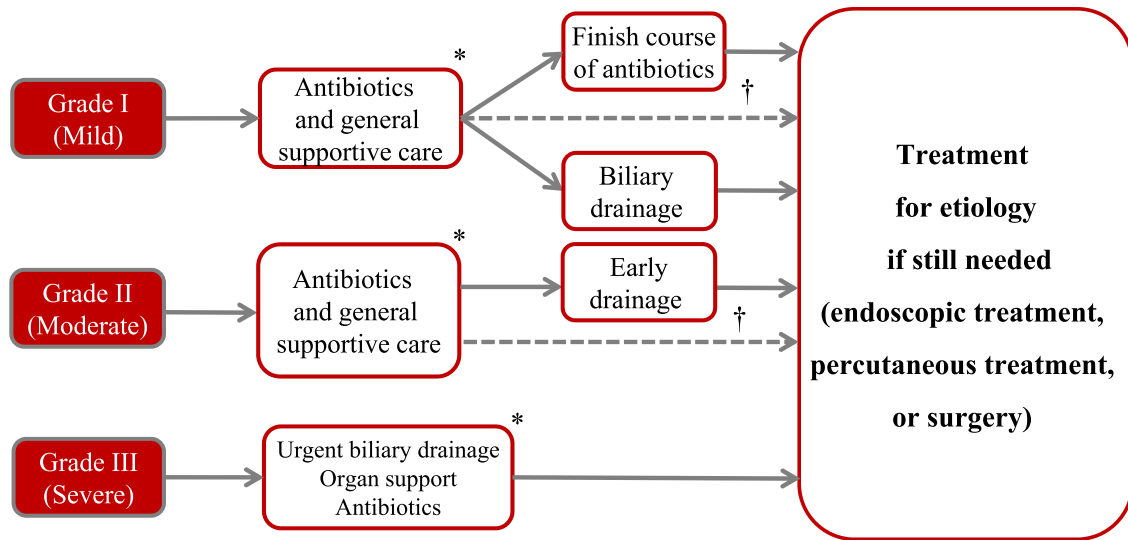
Flowchart for the management of acute cholangitis (Fig. 2)

*Grade I (mild acute cholangitis)*

Mild acute cholangitis is defined as cholangitis that does not meet the TG18 severity assessment criteria for moderate or severe cholangitis below (CPG) [9]. In most cases initial treatment including antibiotics is sufficient, and most patients do not require biliary drainage. However, biliary drainage should be considered if a patient does not respond to initial treatment. EST and subsequent choledocholithotomy may be performed at the same time as biliary drainage. Postoperative cholangitis usually improves with antibiotic treatment alone, and biliary drainage is not usually required (CPG) [12].

*Grade II (moderate acute cholangitis)*

Moderate acute cholangitis is cholangitis that is not severe but requires early biliary drainage. In the TG18 severity



**Fig. 2** TG18 flowchart for the management of acute cholangitis. Cited and modified from Miura et al. [12]. \*Blood culture should be taken into consideration before antibiotics are started. Bile samples should be taken during biliary drainage and cultured. †Principles of treatment for acute cholangitis consist of antimicrobial administration, biliary drainage, and treatment of the etiology. For patients with mild or moderate choledocholithiasis, if possible the etiology should be treated at the same time as biliary drainage is performed

assessment criteria, moderate cholangitis is assessed if at least two of the following five criteria are met: WBC  $\geq 12,000$  or  $< 4,000$ , temperature  $\geq 39^\circ\text{C}$ , age  $\geq 75$  years, total bilirubin  $\geq 5$  mg/dl, or albumin  $< (\text{lower limit of normal value} \times 0.73 \text{ g/dl})$  (CPG) [9].

Early endoscopic or percutaneous transhepatic biliary drainage is indicated. If the underlying etiology requires treatment, this should be provided after the patient’s general condition has improved (CPG) [12], and EST and subsequent choledocholithotomy may be performed together with biliary drainage.

*Grade III (severe acute cholangitis)*

Severe acute cholangitis is cholangitis with sepsis-induced organ damage. In the TG18 severity assessment criteria, severe cholangitis is assessed if any one of the following criteria is met: cardiovascular dysfunction (requiring the use of dopamine  $\geq 5$   $\mu\text{g/kg}$  per min or noradrenaline), neurological dysfunction (disturbance of consciousness), respiratory dysfunction ( $\text{PaO}_2/\text{FiO}_2$  ratio  $< 300$ ), renal dysfunction (oliguria or serum creatinine  $> 2.0$  mg/dl), hepatic dysfunction (PT-INR  $> 1.5$ ), or coagulation disorder (platelet count  $< 10^4/\mu\text{l}$ ) (CPG) [9].

As the patient’s condition may deteriorate rapidly, a swift response is essential including appropriate respiratory/circulatory management (tracheal intubation followed by artificial ventilation and the use of hypertensive agents). Endoscopic or percutaneous transhepatic biliary drainage should be performed as soon as possible after the patient’s condition

has been improved by initial treatment and respiratory/circulatory management. If treatment for the underlying etiology is required, this should be provided after the patient’s general status has improved (CPG) [12].

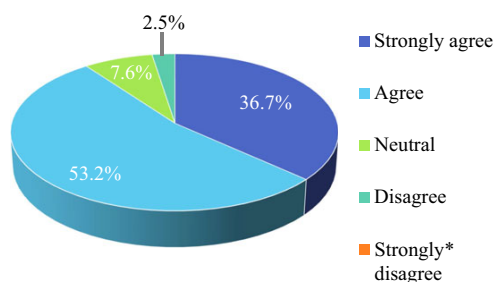
*Transfer criteria*

Table 5 shows the transfer criteria for acute cholangitis. If a hospital is not equipped to perform endoscopic or percutaneous transhepatic biliary drainage or provide intensive care, patients with moderate or severe cholangitis should preferably be transferred to a hospital capable of providing these treatments, irrespective of whether or not they are actually required (CPG) [25].

**Table 5** Transfer criteria for acute cholangitis

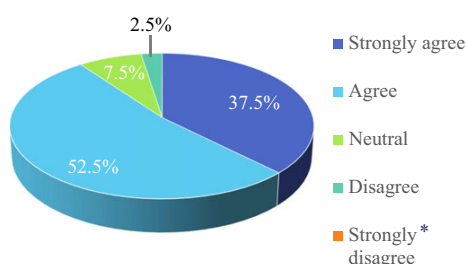
Severe acute cholangitis (Grade III)	Patients who require emergency biliary drainage as well as critical care should be transferred immediately to a hospital where this can be provided
Moderate acute cholangitis (Grade II)	Patients should be treated in a hospital where biliary drainage and systemic management can be performed. If a hospital is not equipped to perform biliary drainage, they should be transferred to a hospital where this can be provided
Mild acute cholangitis (Grade I)	If a calculus is present in the common bile duct or there is no response to initial treatment (within 24 h), a similar response to that for moderate acute cholangitis should be considered

Cited from reference [25]



\* No panelists selected this option.

**Fig. 3** Answers to the question “Do you agree to perform treatment for etiology simultaneously, if possible, with biliary drainage for moderate cholangitis?”. No (Strongly disagree) answers from the panelists



\* No panelists selected this option.

**Fig. 4** Answers to the question “Do you agree to revise flowchart for the management of acute cholangitis?”. No (Strongly disagree) answers from the panelists

## Results of public hearing

At the TG18 public hearing held on 9 June 2017, participants were asked to give their opinions on two questions about the flowchart for acute cholangitis on an answer pad.

To the first question, “Do you agree to perform treatment for etiology simultaneously, if possible, with biliary drainage for moderate cholangitis?” 90% of participants chose either “Strongly agree” or “Agree” as their response (Fig. 3). To the second question, “Do you agree to revise flowchart for the management of acute cholangitis?” 90% also chose either “Strongly agree” or “Agree” as their response (Fig. 4). This was considered to indicate the validity of the changes to the current flowchart.

**Acknowledgments** We express our deep gratitude to the Japanese Society of Hepato-Biliary-Pancreatic Surgery, the Japanese Society of Abdominal Emergency Medicine, the Japanese Society of Surgical Infection, and the Japan Biliary Association, for their substantial support and guidance in the preparation of this article. We also would like to express our deep gratitude to the Japanese Society of Hepato-Biliary-Pancreatic Surgery for the Article Processing Managing Office of the Tokyo Guidelines 18 for preparing this publication. We appreciate all secretariats of the Japanese Society of Hepato-Biliary-Pancreatic Surgery for their technical support.

**Conflict of interest** Goro Honda has received honoraria from Johnson and Johnson and Medtronic.

## Appendix: author’s affiliation

Fumihiko Miura, Tadahiro Takada and Keita Wada, Department of Surgery, Teikyo University School of Medicine, Tokyo, Japan; Kohji Okamoto, Department of Surgery, Center for Gastroenterology and Liver Disease, Kitakyushu City Yahata Hospital, Fukuoka, Japan; Steven M. Strasberg, Section of Hepato-Pancreato-Biliary Surgery, Washington University School of Medicine in St. Louis, St. Louis, MO, USA; Horacio J. Asbun, Department of Surgery, Mayo Clinic College of Medicine, Jacksonville, FL, USA; Henry A. Pitt and David Schlossberg, Lewis Katz School of Medicine at Temple University, Philadelphia, PA, USA; Harumi Gomi, Center for Global Health, Mito Kyodo General Hospital, University of Tsukuba, Ibaraki, Japan; Joseph S. Solomkin, Department of Surgery, University of Cincinnati College of Medicine, Cincinnati, OH, USA; Ho-Seong Han and Yoo-Seok Yoon, Department of Surgery, Seoul National University Bundang Hospital, Seoul National University College of Medicine, Seoul, Korea; Myung-Hwan Kim, Department of Gastroenterology, University of Ulsan College of Medicine, Seoul, Korea; Tsann-Long Hwang, Miin-Fu Chen and Keng-Hao Liu, Division of General Surgery, Linkou Chang Gung Memorial Hospital, Taoyuan, Taiwan; Wayne Shih-Wei Huang, Department of Surgery, Show Chwan Memorial Hospital, Changhua, Taiwan; Seiki Kiriyama, Department of Gastroenterology, Ogaki Municipal Hospital, Gifu, Japan; Takao Itoi and Shuntaro Mukai, Department of Gastroenterology and Hepatology, Tokyo Medical University Hospital, Tokyo, Japan; O James Garden, Clinical Surgery, University of Edinburgh, Edinburgh, UK; Kui-Hin Liao, Liao KH Consulting PL, Mt Elizabeth Novena Hospital, Singapore and Yong Loo Lin School of Medicine, National University of Singapore, Singapore; Akihiko Horiguchi, Department of Gastroenterological Surgery, Fujita Health University School of Medicine, Aichi, Japan; Cheng-Hsi Su, Department of Surgery, Cheng Hsin General Hospital, Taipei, Taiwan; Dirk J. Gouma, Department of Surgery, Academic Medical Center, Amsterdam, The Netherlands; Giulio Belli, Department of General and HPB Surgery, Loreto Nuovo Hospital, Naples, Italy; Christos Dervenis, First Department of Surgery, Agia Olga Hospital, Athens, Greece; Palepu Jagannath, Department of Surgical Oncology, Lila-vati Hospital and Research Centre, Mumbai, India; Angus C. W. Chan, Surgery Centre, Department of Surgery, Hong Kong Sanatorium and Hospital, Hong Kong, Hong Kong; Wan Yee Lau, Faculty of Medicine, The Chinese University of Hong Kong, Shatin, Hong Kong; Itaru



Endo, Department of Gastroenterological Surgery, Yokohama City University Graduate School of Medicine, Kanagawa, Japan; Kenji Suzuki and Taizo Kimura, Department of Surgery, Fujinomiya City General Hospital, Shizuoka, Japan; Eduardo de Santibañes, Department of Surgery, Hospital Italiano, University of Buenos Aires, Buenos Aires, Argentina; Mariano Eduardo Giménez, Chair of General Surgery and Minimal Invasive Surgery “Taquini”, University of Buenos Aires, DAICIM Foundation, Buenos Aires, Argentina; Eduard Jonas, Surgical Gastroenterology/Hepatopancreatobiliary Unit, University of Cape Town and Groote Schuur Hospital, Cape Town, South Africa; Harjit Singh, Department of Hepato-Pancreato-Biliary Surgery, Hospital Selayang, Selangor, Malaysia; Goro Honda, Department of Surgery, Tokyo Metropolitan Komagome Hospital, Tokyo, Japan; Koji Asai and Manabu Watanabe, Department of Surgery, Toho University Ohashi Medical Center, Tokyo, Japan; Yasuhisa Mori, Department of Surgery and Oncology, Graduate School of Medical Sciences, Kyushu University, Fukuoka, Japan; Ryota Higuchi and Masakazu Yamamoto, Department of Surgery, Institute of Gastroenterology, Tokyo Women’s Medical University, Tokyo, Japan; Toshiki Rikiyama, Department of Surgery, Saitama Medical Center, Jichi Medical University, Saitama, Japan; Naohiro Sata, Department of Surgery, Jichi Medical University, Tochigi, Japan; Nobuyasu Kano, Director, Chiba Tokushukai Hospital, Chiba, Japan; Akiko Umezawa, Minimally Invasive Surgery Center, Yotsuya Medical Cube, Tokyo, Japan; Hiromi Tokumura, Department of Surgery, Tohoku Rosai Hospital, Miyagi, Japan; Jiro Hata, Department of Endoscopy and Ultrasound, Kawasaki Medical School, Okayama, Japan; Kazuto Kozaka, Department of Radiology, Kanazawa University Graduate School of Medical Sciences, Kanazawa, Japan; Yukio Iwashita and Masafumi Inomata, Department of Gastroenterological and Pediatric Surgery, Oita University, Faculty of Medicine, Oita, Japan; Taizo Hibi, Department of Surgery, Keio University School of Medicine, Tokyo, Japan; Masamichi Yokoe, Department of General Internal Medicine, Japanese Red Cross Nagoya Daini Hospital, Aichi, Japan; Seigo Kitano, President, Oita University, Oita, Japan; Koichi Hirata, Department of Surgery, JR Sapporo Hospital, Hokkaido, Japan; Yoshinobu Sumiyama, Director, Toho University, Tokyo, Japan; Kazuo Inui, Department of Gastroenterology, Second Teaching Hospital, Fujita Health University, Aichi, Japan.

## References

- Miura F, Takada T, Kawarada Y, Nimura Y, Wada K, Hirota M, et al. Flowcharts for the diagnosis and treatment of acute cholangitis and cholecystitis: Tokyo Guidelines. *J Hepatobiliary Pancreat Surg.* 2007;14:27–34.
- Takada T, Strasberg SM, Solomkin JS, Pitt HA, Gomi H, Yoshida M, et al. TG13: Updated Tokyo Guidelines for the management of acute cholangitis and cholecystitis. *J Hepatobiliary Pancreat Sci.* 2013;20:1–7.
- Okamoto K, Suzuki K, Takada T, Strasberg SM, Asbun HJ, Endo I, et al. Tokyo Guidelines 2018: flowchart for the management of acute cholecystitis. *J Hepatobiliary Pancreat Sci.* 2018;25:55–72.
- Kiriyama S, Takada T, Strasberg SM, Solomkin JS, Mayumi T, Pitt HA, et al. New diagnostic criteria and severity assessment of acute cholangitis in revised Tokyo Guidelines. *J Hepatobiliary Pancreat Sci.* 2012;19:548–56.
- Kiriyama S, Takada T, Strasberg SM, Solomkin JS, Mayumi T, Pitt HA, et al. TG13 guidelines for diagnosis and severity grading of acute cholangitis (with videos). *J Hepatobiliary Pancreat Sci.* 2013;20:24–34.
- Kiriyama S, Kozaka K, Takada T, Strasberg SM, Pitt HA, Gabata T, et al. Tokyo Guidelines 2018: diagnostic criteria and severity grading of acute cholangitis (with videos). *J Hepatobiliary Pancreat Sci.* 2018;25:17–30.
- Yokoe M, Takada T, Strasberg SM, Solomkin JS, Mayumi T, Gomi H, et al. New diagnostic criteria and severity assessment of acute cholecystitis in revised Tokyo Guidelines. *J Hepatobiliary Pancreat Sci.* 2012;19:578–85.
- Yokoe M, Takada T, Strasberg SM, Solomkin JS, Mayumi T, Gomi H, et al. TG13 diagnostic criteria and severity grading of acute cholecystitis (with videos). *J Hepatobiliary Pancreat Sci.* 2013;20:35–46.
- Yokoe M, Hata J, Takada T, Strasberg SM, Asbun HJ, Wakabayashi G, et al. Tokyo Guidelines 2018: diagnostic criteria and severity grading of acute cholecystitis (with videos). *J Hepatobiliary Pancreat Sci.* 2018;25:41–54.
- Charlson ME, Pompei P, Ales KL, MacKenzie CR. A new method of classifying prognostic comorbidity in longitudinal studies: development and validation. *J Chronic Dis.* 1987;40:373–83.
- American Society of Anesthesiologists. ASA Physical Status Classification System. Available from URL: <https://www.asahq.org/resources/clinical-information/asa-physical-status-classification-system>.
- Miura F, Takada T, Strasberg SM, Solomkin JS, Pitt HA, Gouma DJ, et al. TG13 flowchart for the management of acute cholangitis and cholecystitis. *J Hepatobiliary Pancreat Sci.* 2013;20:47–54.
- Thomas SH, Silen W, Cheema F, Reisner A, Aman S, Goldstein JN, et al. Effects of morphine analgesia on diagnostic accuracy in Emergency Department patients with abdominal pain: a prospective, randomized trial. *J Am Coll Surg.* 2003;196:18–31.
- Gallagher EJ, Esses D, Lee C, Lahn M, Bijur PE. Randomized clinical trial of morphine in acute abdominal pain. *Ann Emerg Med.* 2006;48:150–60, 160.e1–4.
- Gomi H, Solomkin JS, Schlossberg D, Okamoto K, Takada T, Strasberg SM, et al. Tokyo Guidelines 2018: antimicrobial therapy for acute cholangitis and cholecystitis. *J Hepatobiliary Pancreat Sci.* 2018;25:3–16.
- Kiriyama S, Takada T, Miura F, Gomi H, Itoi T, Yokoe M. Clinical application and verification of TG 13 diagnostic criteria and severity assessment among patients with acute cholangitis: an international multi center observational study. *J Hepatobiliary Pancreat Sci.* 2017;24:329–37.
- Jang SE, Park SW, Lee BS, Shin CM, Lee SH, Kim JW, et al. Management for CBD stone-related mild to moderate acute cholangitis: urgent versus elective ERCP. *Dig Dis Sci.* 2013; 58:2082–7.
- Eto K, Kawakami H, Haba S, Yamato H, Okuda T, Yane K, et al. Single-stage endoscopic treatment for mild to moderate

- acute cholangitis associated with choledocholithiasis: a multicenter, non-randomized, open-label and exploratory clinical trial. *J Hepatobiliary Pancreat Sci*. 2015;22:825–30.
19. Ito T, Sai JK, Okubo H, Saito H, Ishii S, Kanazawa R, et al. Safety of immediate endoscopic sphincterotomy in acute suppurative cholangitis caused by choledocholithiasis. *World J Gastrointest Endosc*. 2016;8:180–5.
  20. Lee JC, Moon JH, Choi HJ, Kim DC, Choi MH, Lee TH, et al. Delayed endoscopic papillary large balloon dilation after sphincterotomy for removing large bile duct stones in patients with acute cholangitis. *Dig Dis Sci*. 2014;59:1302–6.
  21. Zhu B, Wang Y, Gong K, Lu Y, Ren Y, Hou X, et al. Comparison of emergent versus elective laparoscopic common bile duct exploration for patients with or without nonsevere acute cholangitis complicated with common bile duct stones. *J Surg Res*. 2014;187:72–6.
  22. Zhu B, Li D, Ren Y, Li Y, Wang Y, Li K, et al. Early versus delayed laparoscopic common bile duct exploration for common bile duct stone-related nonsevere acute cholangitis. *Sci Rep*. 2015;5:6.
  23. Suetani K, Okuse C, Nakahara K, Michikawa Y, Noguchi Y, Suzuki M, et al. Thrombomodulin in the management of acute cholangitis-induced disseminated intravascular coagulation. *World J Gastroenterol*. 2015;21:533–40.
  24. Nakahara K, Okuse C, Adachi S, Suetani K, Kitagawa S, Okano M, et al. Use of antithrombin and thrombomodulin in the management of disseminated intravascular coagulation in patients with acute cholangitis. *Gut Liv*. 2013;7:363–70.
  25. The revision committee for the guidelines of acute cholangitis and cholecystitis. *Guidelines of acute cholangitis and cholecystitis 2013*. Tokyo: Igakutosho-shuppan Ltd.; 2013 in Japanese.